

Computerized tomographic assessment and clinical evaluation in shoulder instability treated with the Latarjet-Patte procedure using one screw and washer

Fabio Cautiero¹
Raffaele Russo¹
Francesco Di Pietto²
Giuseppe Sabino³

¹ Orthopaedic and Traumatology Department, Pellegrini Hospital, Naples, Italy

² Diagnostic of Imaging Department, Cardarelli Hospital, Naples, Italy

³ Diagnostic of Imaging, Villa Fiorita Clinic, Capua (CE), Italy

Corresponding author:

Fabio Cautiero
Traumatology and Ortopaedic Surgery,
Pellegrini Hospital
Via Portamedina 41
80134 Napoli, Italy
E-mail: fabiocau@inwind.it

Summary

Background: The Latarjet-Patte (L-P) procedure is indicated in anterior instability of the shoulder with a glenoid or humeral bone loss. Our purpose is to evaluate clinical outcome and computerized tomographic (CT) findings as position and resorption of the graft and articular degeneration.

Methods: From 2006 to 2009 50 patients underwent to L-P, 48 was contacted by telephone and 26 were available for follow-up (3 to 6 years). Quick-DASH and Rowe scores was used, 22 patients perform CT.

Results: None of contacted patients reported a new dislocation. The clinical outcome in the 26 followed patients was excellent: mean Quick DASH score: 1.9; mean ROWE score was 94.7. CT scans showed no evidence of articular degeneration of humeral head. There was partial resorption of the graft in 13 patients. We found a correlation between the zone of partial resorption and position of the graft.

Conclusions: CT scan is appropriate to study position and the healing of coracoid graft. A correct choice of where to place the graft together with a wide bone contact and stable synthesis does not

cause degenerative changes after 6 years in our series.

Level of the evidence: IV.

KEY WORDS: shoulder bone loss, shoulder CT assessment.

Introduction

The shoulder is a high mobility joint, so it's susceptible to dislocation and represents the more common site of joints dislocation. When instability is recurrent or it's a cause of pain and/or functional impairment the surgical stabilization is required.

The *Latarjet procedure* was described by prof. Latarjet¹ in the 1950 and uses a large coracoid bone graft to stabilize the shoulder.

Later prof. Patte^{2,3} proposed a "*Triple effect*" to explain the reason of the incremented stability of the shoulder with this surgical procedure:

- The bone effect or the extending of glenoid arch, that prevent the engaging of Hill-Sachs lesion and increase the extension of glenoid bone;
- The muscle effect is related to the increased tension of the lower fibres of subscapularis tendon due to conjoined tendon particularly in abduction and external rotation of the shoulder;
- With "*Capsular effect*" is described the repair of the capsule and posterior capsule constraint the avoid anterior dislocation or engaging of Hill-Sachs lesion.

An other factor than increased the anterior stability of the shoulder in which a Latarjet-Patte procedure is performed is the "*Sling effect*" of conjoined tendon that slings across the antero-inferior capsule when the shoulder is abducted of 90° and in external rotation of 90°.

Surgical technique

Patient is placed in beach chair position and a small pillow is placed under the scapula to have a great view on glenoid and to identify easier the coracoid.

The skin is incised at the tip of coracoid extending inferiorly for 4 cm generally. Deltopectoral interval is identify and cephalic vein is closed to prevent postoperative hematoma.

A Hohman retractor is placed on the top of coracoid, the coraco acromial ligament is detached 1 cm to coracoid insertion (Fig. 1a). So the pectoralis minor tendon is carefully detached from coracoid until to expose the elbow of coracoid process (Fig. 1b).

A sagittal saw with a 90° angled blade perform the coracoid osteotomy at the elbow, the incision of coraco-humeral ligament with the release of lateral border of conjoined tendon allows the coracoid to be more mobile (Fig. 1c).

The coracoid graft is prepared by removing soft tissues from its deep-surface and performing an accurate decortication to have a wide view of bone surface. Subsequently we use a 1.8 mm K-wire first and 3,2 mm drill later to create a hole in the center of the graft (Fig. 1d). Two n° 2 adsorbable sutures are used to identify the coraco acromial ligament attached on coracoid graft. We use two holes for two screws only if graft length is more than 2,5 cm. We measure the distance of hole from anterior bone edge of coracoid graft closer to coraco acromial attach.

With arm at side and in external rotation we identify the inferior border of subscapularis tendon highlight-

ed by the called “three sister” (artery and vein) and we open subscapularis muscle along its fibers at the intersection of middle with inferior third, been safe to divide muscle by capsule, a special retractor namely “Gelpy” is inserted between muscle fibers. The capsulotomy is performed generally vertically parallel to anterior glenoid rim: if the patient is hyperlax we perform an L capsulotomy to reduce anterior camera. We use a Fukuda retractor to put away the humeral head and a Steinmann pin into the neck of the scapula to put away the superior portion of subscapularis.

Once that glenoid anterior half is well viewed we prepare the bed of coracoid graft. The anterior labrum is incised, periosteum and Bankart lesion are removed (Fig. 2a). We finalize the exposure with an osteotome to slightly have a rough surface to increase the healing process.

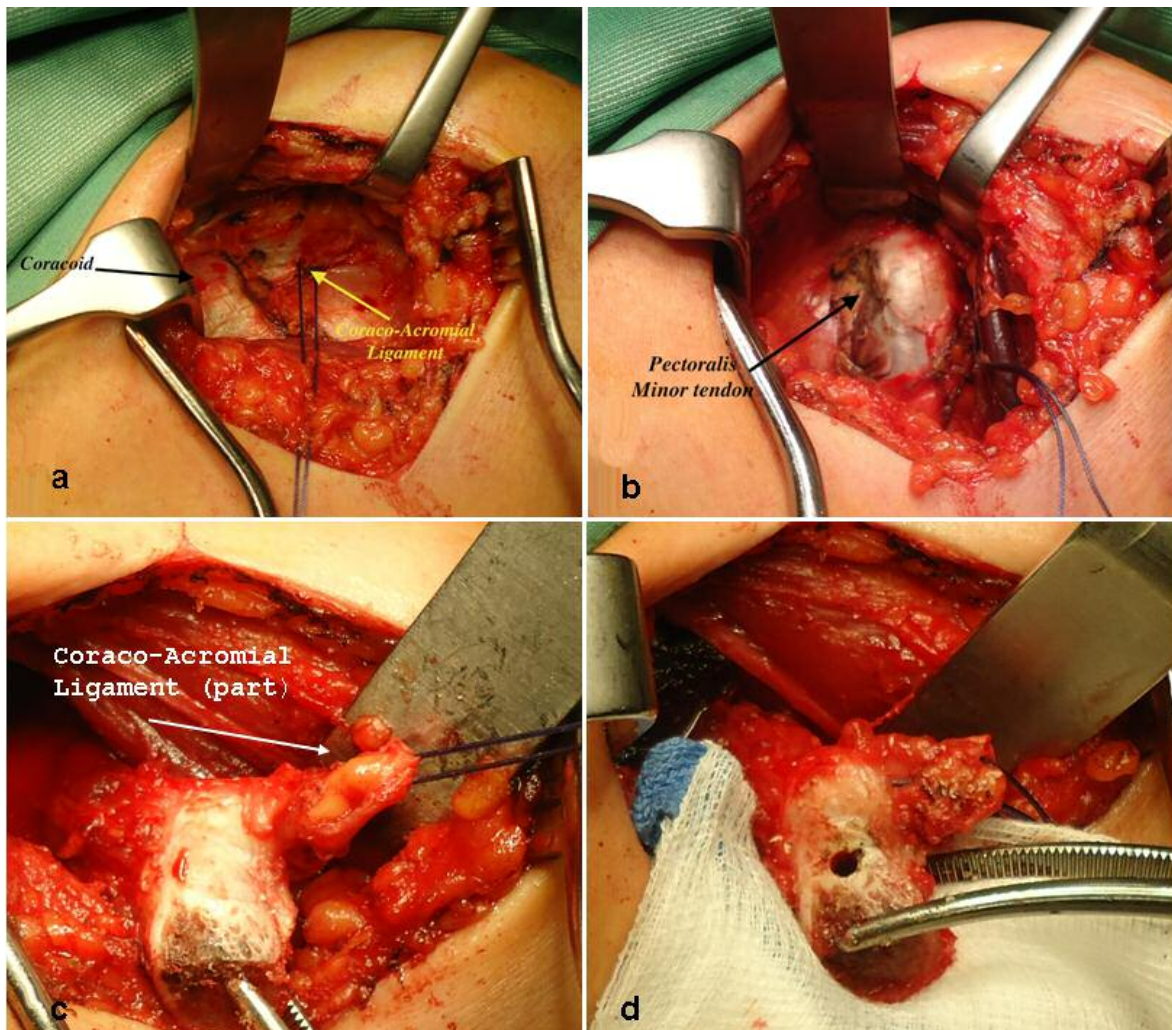


Figure 1. Surgical view, left shoulder: a. Exposing of coraco-acromial ligament, adsorbable suture is used to identify the ligament; b. Detachment of pectoralis minor tendon (arrow); c. Coracoid is osteotomised at the elbow and the suture is used to mark the part of ligament necessary to perform the capsular shift; d. Using a 3,2 mm drill to create a hole in the center of the graft.

We drill with a 2.8 mm wire the anterior glenoid neck at the same distance measured on the coracoid graft and we use this wire to calculate the depth. So the coracoid graft with a K wire is put in performed hole and stabilized with a partial threaded screw (diameter 4.0) with a washer (Fig. 2b).

A curve Kocker clamp is used to maintain the graft in the desired rotation during the later step of screwed. A finger is our probe to test the position of the graft, at the articular surface or one millimeter medial. The sutures of ligament attached on coracoid graft are used to perform the “bankart procedure”, that is passed through the capsule and the inferior glenohumeral ligament (Fig. 2c, d).

After the surgery the patient wears a brace standard shoulder brace in internal rotation for a total of 25 days. Starting from the second week begins water rehabilitation protocol with, at first, only forward

flexion movements in moderate abduction. The extreme external rotation is prohibited for 3-4 months.

Materials and methods

Study population and inclusion criteria

From 2006 to 2009, 50 patients with anterior glenohumeral instability underwent an open Latarjet-Patte procedure at our hospital.

The Recurrent Instability was traumatic in the 87%, left shoulder was involved in the 54%, patient was male in 92% and the mean age of patients was 25.9 years (range: 18 to 46).

The number of shoulder dislocation before surgery was “less than ten” in 25 (50%); “between ten and twelve” in 20 (40%), while only the 10% of patients (n=5) reported a number of dislocation “more than twelve”. The 30%

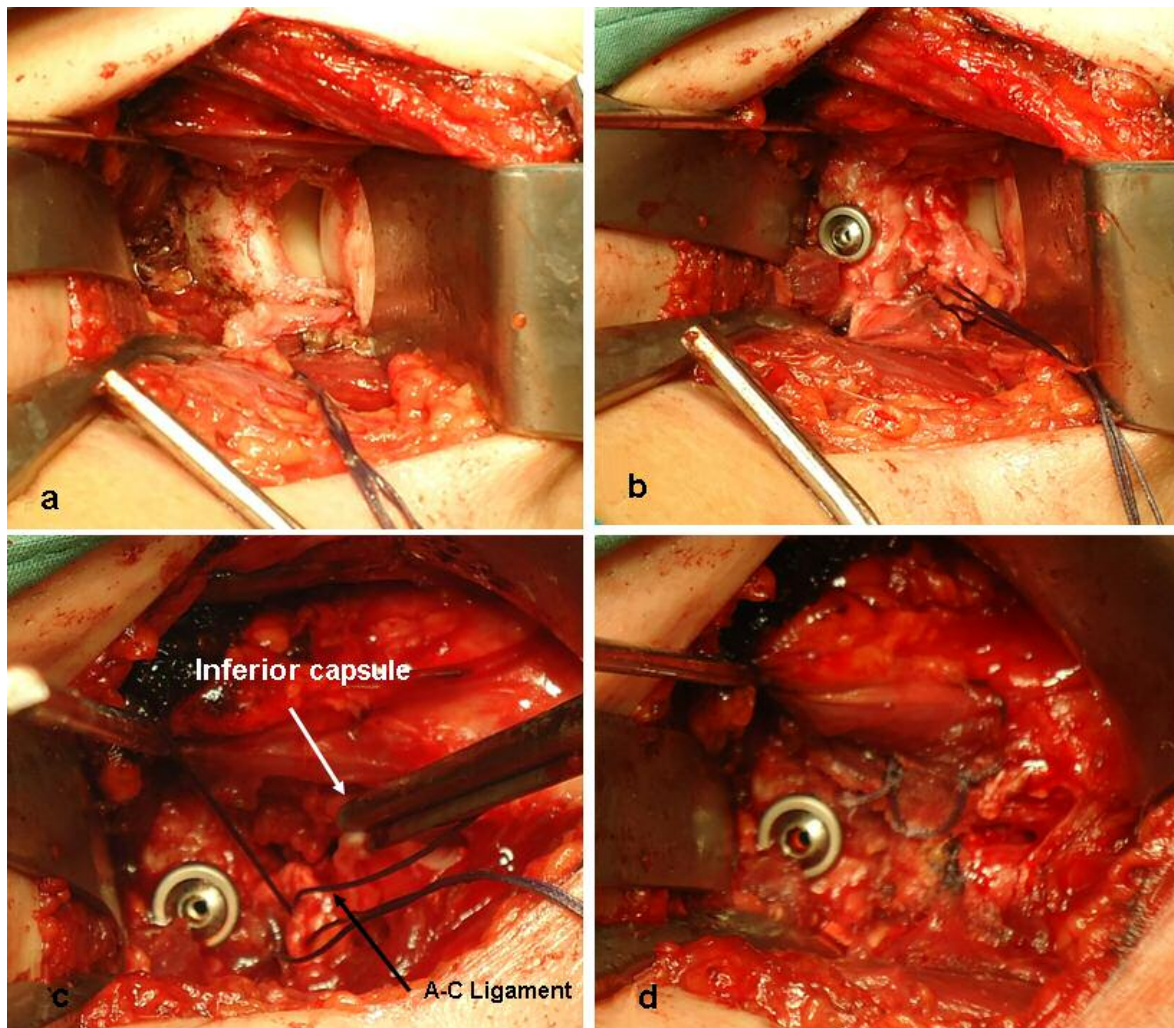


Figure 2. Surgical view, left shoulder: a. Preparation of “coracoid graft bed”: the anterior labrum is incised, periosteum and Bankart lesion are removed; b. Graft is synthesized to glenoid bone with cannulated screw and a washer; c. A portion of A-C ligament detached from acromion is used to reinforce the capsule and to perform a re-tensioning of the inferior glenohumeral ligament; d. Final aspect of reconstruction of anterior capsule.

of patients participated in sport activity.

Inclusion criteria to perform the Latarjet-Patte procedure were:

- Glenoid Bone loss higher than 15% at CT Assessment according to "PICO method"⁴ or Humeral Bone loss (Hill-Sachs) higher than 1/3;
- Competitive participation in contact sport or those involving forced overhead activity;
- Capsular lesion or HAGL lesion;
- Excessive thinness of capsular tissue;
- Failure of arthroscopic stabilization;
- Dislocation with glenoid fracture (bony Bankart).

Exclusion criteria were:

- Large glenoid fractures (more than 1/3)
- Subscapularis rupture.

Purpose and clinical assessment

The purpose of this study was to report the clinical results of modified Latarjet-Patte procedure performed with one screw and a washer and to investigate about CT findings regarding location and osteolysis of the graft, possible articular damages and the reshaping of the glenoid inverted pear.

Our hypothesis is that the healing of the graft follows the humeral-glenoid track, in the area of contact with humeral head, so very large graft stabilized with two screws it's no even required but is necessary to put the graft in right place.

We contact at telephone interview 48 patients. Twenty-six shoulder in 25 patients (1 bilateral) were evaluated at a minimum follow-up of 3 years (mean FU: 53 months, range 3 to 6 years).

Patients were evaluated clinically with Quick-DASH and Rowe Scores and the Range of Movement (ROM) of the shoulder was determined.

22 patient agree to perform CT assessment to determine the exact position and resorption of the coracoid transfer, the reshaping of glenoid bone and any articular degeneration signs.

Ethics

This study meets the international ethical standards as required by the Journal⁵.

CT assessment

Patients were evaluated by Multi Slice Computed Tomography (GE Lightspeed 16 slice - General Electric Medical Systems, Milwaukee, Wisconsin, USA).

CT was conducted with following parameters: 0.65 mm thickness, 120 Kv, Pitch 0,9, 250 mA, Gap 0 mm. We performed post-processing analysis using Osirix software.

MPR reconstructions were performed by sagittal and oblique-axial planes along the sagittal axis of the screw and parallel to the glenoid articular surface to determine the following parameters:

- articular degeneration (multiple scans);
- axial position of the coracoid transfer (axial oblique scan);
- resorption of the coracoid transfer (sagittal scan);
- distance between the graft and the glenoid anterior edge (sagittal and axial oblique scan);

- fusion of the coracoid transfer (sagittal scan);
- position of the screw (sagittal and axial scan);
- bone resorption close to the screw (multiple scans).

To evaluate the location of the graft, we evaluated CT scan booth in the trasversal and coronal plane. The osteolysis of the coracoid was determined by assessing bone resorption around the screw that is ever drilled in the central of the graft.

We aimed to find a correlation between longitudinal position of the screw and the resorption of the graft, to analyse if early signs of osteoarthritis could be correlated to lateral position of the graft in the axial plane relative to the edge of the glenoid articular surface and to investigate about graft healing and resorption with the reshaping of glenoid area.

To evaluate the position of the coracoid transfer we traced the circle used to determine the analysis of the PICO. The measure was performed on a sagittal plane just proximal to the articular surface in the point where the coracoid process became visible^{6,7}. We created a sagittal oblique plane of the glena by MPR reconstruction, without exceeding the inferior circular edge, the anterior and posterior line of the glenoid. We created a craniocaudal division of the circle in 8 different areas: the first line was traced dividing the circle in two halves, a superior and an inferior one; then two lines divided the superior and the inferior part in 4 halves^{8,9}. We counted the 8 longitudinal areas in the PICO circle from the top to the bottom, the line between zone 4 and zone 5 represents the center of the circle (Fig. 3). We considered the position of the screw as the centre of the graft and described its location in the PICO area.

To better calculate correlation index we converted the position of the graft in a binomial variable, assigning the value 1 to the graft positioned above the central line in the PICO area and 0 to the graft located below this line.

We assigned a score to the differents parameters that we have to investigate: osteoarthritis, position and re-

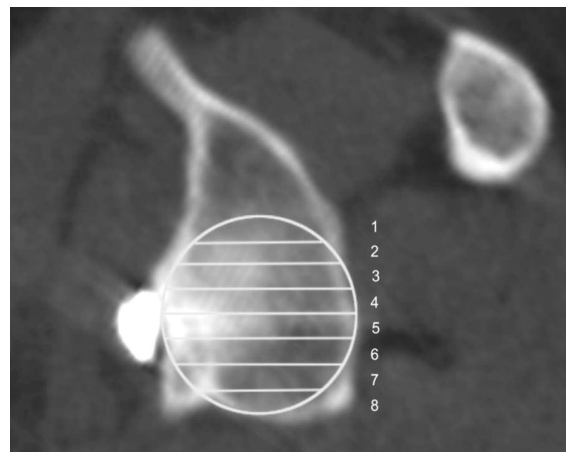


Figure 3. CT image PICO. Reformatted scan, the circle areas.

Table I. Scores that we have assigned to each parameter evaluated: signs of osteoarthritis; position of the graft in the axial plane and resorption of the graft. For each parameter is provided an evaluation board and a score as shown in theTable.

Signs of osteoarthritis	Position of the graft in the axial plane	Resorption of the graft
No Osteoarthritis = 0	Graft > 1mm medial to the articular surface = -1	No resorption = 0
Subtle subchondral sclerosis = 1	Graft between 2 and 3 mm medial = -2	Partial resorption proximal = 1
Microgeodes = 2	Graft > 3 mm medial = -3	Subtotal resorption proximal = 1
Evident Geodes and osteophytes =3	Optimal position of the graft at the level of the articular edge of 1 mm medial = 0	Total resorption proximal = 1
	Graft < 1mm lateral to the articular surface = 1	partial resorption distal = -1
	Graft between 1 and 2 mm lateral = 2	subtotal resorption distal = -2
	Graft > 2 mm lateral = 3	total resorption distal = -3

sorption of the graft (Tab. I); we adopted Spearman's index to calculate a correlation.

The following score was assigned to each patient according to the signs of osteoarthritis in CT images: No osteoarthritis=0; Subtle subchondral sclerosis=1; Microgeodes=2; Evident geodes and osteophytes=3.

We assigned the following score to the position of the transfer in the axial plane relative to the edge of the articular glenoid surface: Graft > 1 mm medial to the articular surface=-1; Graft between 2 and 3 mm medial=-2; Graft > 3 mm medial=-3; Optimal position of the graft at the level of the articular edge of 1 mm medial=0; Graft < 1mm lateral to the articular surface=1; Graft between 1 and 2 mm lateral=2; Graft > 2 mm lateral=3.

We considered 4 degrees of resorption of the graft, in relation to the area of extension, in the superior or inferior part: Score of the resorption in the superior part of the graft: 0=no resorption; 1=partial resorption; 2=subtotal resorption; 3=total resorption.

Score of the resorption in the inferior part of the graft: 0=no resorption; -1=partial resorption; -2=subtotal resorption; -3=total resorption.

Results

Clinical results

No one reported new dislocation at telephone interview of 48 patients. Clinical outcome of followed patients was very satisfactory with excellent results (Fig. 4). The mean Quick-Dash Score was 1.9, Rowe Score (mean) was 94.7. All patients involved in sport activities returns to perform it; the level of sport performance referred by patients it's satisfactory. We found a limitation of ROM about extrarotation in

46% of patients reviewed, with a mean of 13° in ER1 and 12° in ER2 (Fig. 5). The intrarotation and anterior flexion was softly impaired in 17% and 12 % of series respectively. Mean of limitation are shown in Table II.

Radiology results

In 19 patients there was a complete fusion of the graft. In 3 patients it was incomplete.

In 5 patients we found subchondral cists on the graft side (3-16 mm).

In 4 patients we found signs of structural alteration of articular surface of the glena: two patients showed subtle subchondral sclerosis (grade 1), two patients microgeodes (grade 2).

No evidence of articular degeneration of humeral head was observed, so this finding may be an expression of the process of remodeling bone graft.

On the axial plan, in one patient the screw was less than 1 mm lateral to the glenoid surface (grade 1 according to our grading), in one patient it was between 1 and 2 mm lateral (grade 2).

Partial resorption of the graft was found in 13 patients and in the cranial area of the graft; 9 patients had no resorption.

Regarding the position in the PICO circle areas, in 17 patients the graft occupied mainly the inferior part of the circle (positions from 5 to 8). In 5 patients the transfer extended in the first superior area (position from 1 to 4). The main position in which we found the screw (the centre of the graft) was in the area number 5, namely the area immediately inferior to the centre of the PICO circle.

Position of the graft above the central line in the PICO area significantly correlated with its resorption in the cranial portion; $p=0.8367$ $p<0.01$. We did not found any resorption in the inferior part of the graft.

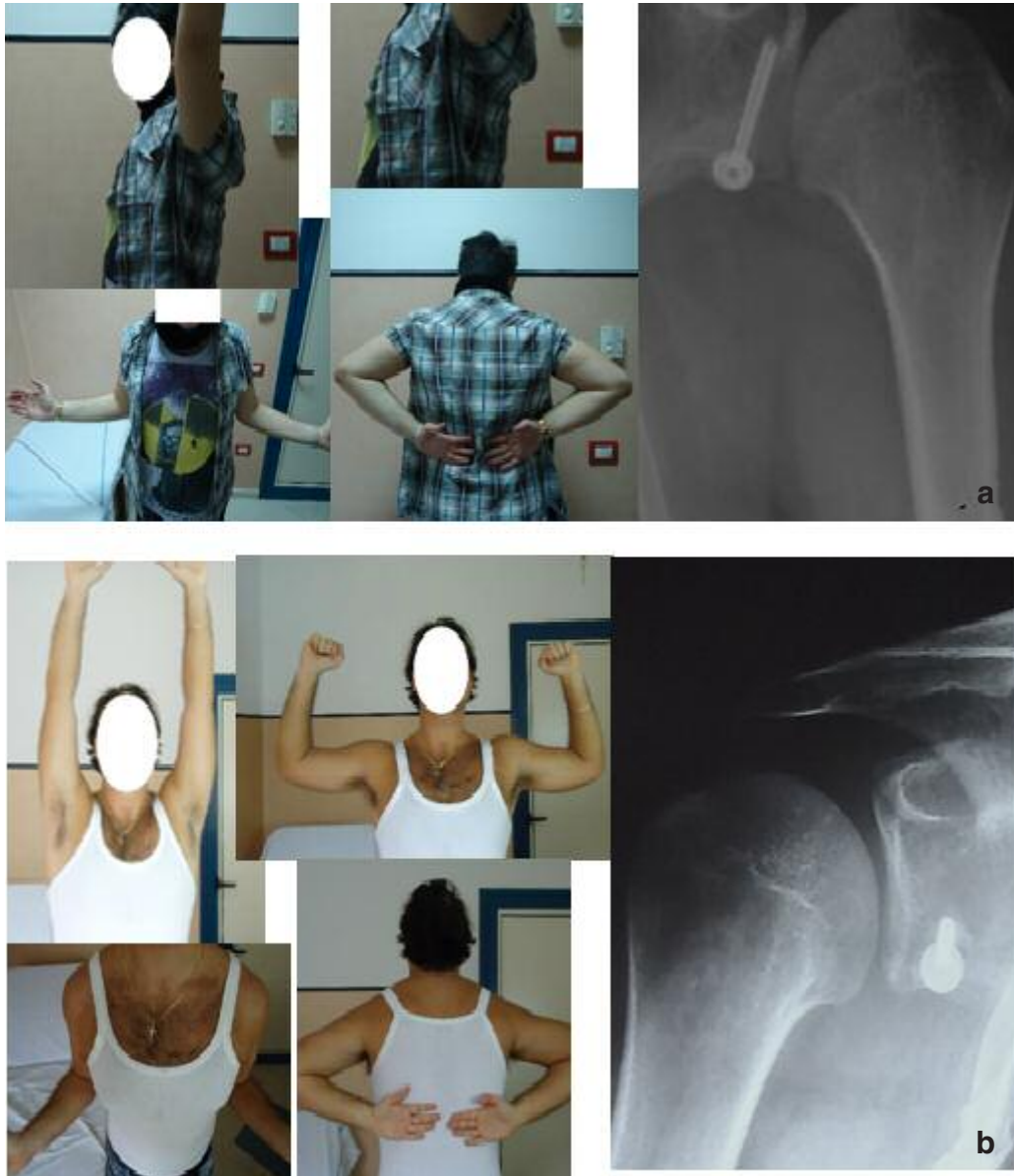

Figure 4. Clinical results. Examples of two patients with complete recovery of ROM of affected shoulder: a. Left shoulder; b. Right shoulder.

Discussion

In this paper we report the clinical outcome of Latarjet-Patte procedure performed with one screw and a washer in coracoid graft less or equal than 2,5 cm. Our aim is also to collect CT data of patients who underwent surgery to study the position and resorption of coracoid graft.

We report a very satisfactory clinical outcome in the patients of our series, no one has reported a new dislocation, we found a little functional impairment that don't impact in the life or sport activity of the patients (see results).

In our opinion to obtain a stable shoulder it's required to restore the bone stock in the area of the gleno-

humeral track. This is confirmed by CT scan results that showed a resorption of the graft in the area of no contact between humeral head and glenoidal surface. Infact we report a more frequent rate of partial resorption of coracoid graft when it's localized in the more proximal area of glenoid and the resorption is ever in the cranial part of the graft. The CT study it's necessary to asses the position of the graft in the coronal, trasversal and sagittal planes and in this paper we propose a reproducibility method to do it.

This paper has limitation of a small number of patients, no control series performed with two screws. The strain of study stay in the very omogenous group of patients with same surgical procedure and same osteosynthesis device. No other study about Latarjet-

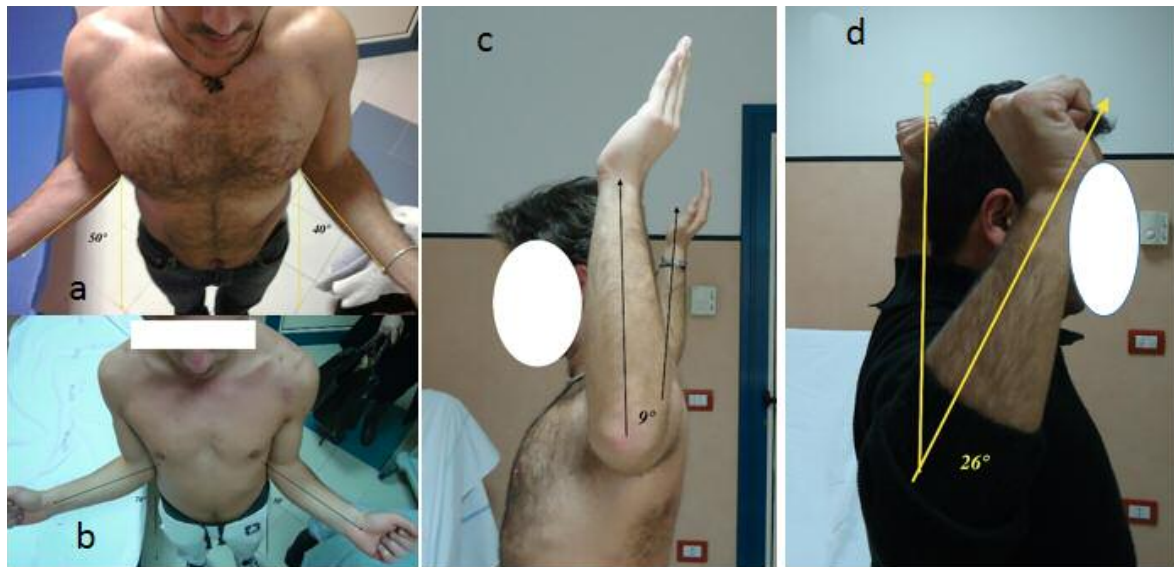


Figure 5. Clinical results. Example of slight impairment of extrarotation of the shoulder: a. Left shoulder limitation of 10° in ER1 position; b. Left shoulder limitation of 20° in ER1 position; c. Left shoulder limitation of 9° in ER2 position; d. Right shoulder limitation of 26° in ER2 position.

Table II. Clinical results with highlighted slight functional impairment of the ROM in the various plane.

<i>Limitation of ROM</i>	<i>Percentage of Patients</i>	<i>Degree</i>
EXTRAROTATION	46%	ER1: mean 13° (range 5 to 20) ER2: mean 12° (range 5 to 26)
INTRAROTATION	17%	L2-L3
ANTERIOR FLEXION	12%	Mean 18° (range 10 to 25)

Patte procedure performed with one screw and washer with CT assessment is reported in Literature.

It is widely accepted that patients affected by shoulder anterior instability with bone loss have an high incidence of failure and dislocations if treated with arthroscopic stabilization¹⁰⁻¹².

Several risk factors have been identified in recurrent instability after surgical stabilization procedures. The most commons accepted are: young age, contact or overhead sports, capsular quality tissues, hyperlaxity, number of previous dislocations, humeral and glenoideal bone loss.

Burkhart et al.¹² report 67% of recurrence rate after arthroscopic Bankart repair in patients with significant bone loss.

Itoi¹³ and several papers^{14,15} confirmed the biomechanical importance of bone defect in unstable shoulder and necessity of bone grafts in the treatment.

The Latarjet-Patte procedure (and modified version) represents a reliable and effective surgery to treat severe shoulder instability, particularly in presence of bone loss and bone defect¹⁶⁻²⁰.

This procedure is commonly used also in cases of failure of arthroscopic repair. When arthroscopic stabilization failing to increase stability of the shoulder a new arthroscopic approach in not raccomandabile in all the cases, also in absence of great bone loss²¹.

Patte described in 1980 stabilizing mechanism of Latarjet proposing the triple-blocking effect²; Yamamoto later²² in cadaveric study found that sling effect was the most important and bone effect much less.

A low rate of failure is reported in literature (non-union, recurrent dislocation, graft fracture) when surgical procedure is performed correctly and the transplant does not protrude beyond the articular rhyme. The position too lateral of the coracoid graft is in fact associated with

the manifestation degenerative arthrosis.

The glenoidal bone loss (bony bankart in acute fracture or inverted pear in chronic recurrent instability) is evident in radiographic study only in west point²³ and bernageau views²⁴.

The CT is the widely accepted imaging technique to recognize the bone loss, but there isn't clarity on the quantification method. Over the years several techniques for the assessment of glenoidal bone loss have been proposed, the newest PICO technique and evaluation of bilateral and unilateral using TC in 3D mode²⁵. According to our results a graft of 2-2,5 cm synthesized with one screw and washer and positioned in the right place it's sufficient in our series to restore bone stock and avoid dislocations. It's essential to put the graft very closer to articular rim remaining slightly medial to prevent osteoarthritis. The use of washer it's indispensable to amplify the area of compression of the graft on glenoid by the screw.

The CT seems to be necessary to study the bone loss before the surgical treatment and after the surgery (two-three months) to obtain further information about the correct healing of the graft and to test the restoring of glenoidal bone stock.

The bone loss of humeral part (Hill-sachs) change the gleno-humeral track and influences in the mechanism of shoulder instability. More studies are needed to better define the importance of the humeral bone loss than the glenoid and to find a method to quantify it.

Conflict of interest

No relationships/conditions/circumstances that present potential conflict of interest.

References

1. Latarjet M. Treatment of recurrent dislocation of the shoulder. *Lyon Chir.* 1954;49:994-1003.
2. Patte D, Debeyre J. Luxations recidivantes de l'épaule. *Encycl Med Chir. Paris-Technique chirurgicale. Orthopédie.* 1980;44265.
3. Patte D, Bernageau J, Bancel P. The anteroinferior vulnerable point of the glenoid rim, in Bateman JE, Welsch RP (eds): *Surgery of the Shoulder.* New York, NY, Marcel Dekker. 1985;94-99.
4. Baudi P, Righi P, Bolognesi D, et al. How to identify and calculate glenoid bone deficit. *Chir Organi Mov.* 2005;90:145-152.
5. Padulo J, Oliva F, Frizziero A, Maffulli N. *Muscle, Ligaments and Tendons Journal - Basic principles and recommendations in clinical and field science research: 2016 update.* *MLTJ.* 2016;6(1):1-5.
6. Griffith JF, Antonio GE, Yung PS, et al. Prevalence, pattern, and spectrum of glenoid bone loss in anterior shoulder dislocation: CT analysis of 218 patients. *AJR Am J Roentgenol.* 2008;190(5):1247-1254.
7. Griffith JF, Antonio GE, Tong CW, Ming CK. Anterior shoulder dislocation: quantification of glenoid bone loss with CT. *AJR Am J Roentgenol.* 2003;180(5):1423-1430.
8. Cassagnaud X, Maynou C, Mestdagh H. Results of 106 Latarjet-Patte procedures: computed tomography analysis at 7.5 years follow-up. *J Bone Joint Surg Br.* 2002;84(suppl 1):39.
9. Di Giacomo G, Costantini A, de Gasperis N, et al. Coracoid graft osteolysis after the Latarjet procedure for anteroinferior shoulder instability: a computed tomography scan study of twenty-six patients. *J Shoulder Elbow Surg.* 2011;20(6):989-995.
10. Boileau P, Villalba M, Héry JY, Balg F, Ahrens P, Neyton L. Risk factors for recurrence of shoulder instability after arthroscopic Bankart repair. *J Bone Joint Surg Am.* 2006;88(8):1755-1763.
11. Balg F, Boileau P. The instability severity index score. A simple pre-operative score to select patients for arthroscopic or open shoulder stabilisation. *J Bone Joint Surg Br.* 2007;89(11):1470-1477.
12. Burkhart SS, De Beer JF. Traumatic glenohumeral bone defects and their relationship to failure of arthroscopic Bankart repairs: significance of the inverted-pear glenoid and the humeral engaging Hill-Sachs lesion. *Arthroscopy.* 2000;16(7):677-694.
13. Itoi E, Lee SB, Berglund LJ, Berge LL, An KN. The effect of a glenoid defect on anteroinferior stability of the shoulder after Bankart repair: a cadaveric study. *J Bone Joint Surg Am.* 2000;82(1):35-46.
14. Beran MC, Donaldson CT, Bishop JY. Treatment of chronic glenoid defects in the setting of recurrent anterior shoulder instability: a systematic review. *J Shoulder Elbow Surg.* 2010;19(5):769-780.
15. Bigliani LU, Newton PM, Steinmann SP, Connor PM, McIlveen SJ. Glenoid rim lesions associated with recurrent anterior dislocation of the shoulder. *Am J Sports Med.* 1998;26(1):41-45.
16. Burkhart SS, De Beer JF, Barth JR, Cresswell T, Roberts C, Richards DP. Results of modified Latarjet reconstruction in patients with anteroinferior instability and significant bone loss. *Arthroscopy.* 2007;23(10):1033-1041. Erratum in: *Arthroscopy.* 2007;23(12):A16. Criswell, Tim [corrected to Cresswell, Tim].
17. Edwards TB, Walch G. The Latarjet procedure for recurrent anterior shoulder instability: rationale and technique. *Operative Techniques in Sports Medicine.* 2002;10(1):25-32.
18. De Beer JF, Roberts C. Glenoid bone defects-open Latarjet with congruent arc modification. *Orthop Clin North Am.* 2010;41(3):407-415.
19. Matthes G, Horvath V, Seifert J, et al. Oldie but goldie: Bristow-Latarjet procedure for anterior shoulder instability. *J Orthop Surg (Hong Kong).* 2007;15(1):4-8.
20. Přikryl P, Selucký J, Grénar J, Skácel P. Latarjet procedure for the treatment of inveterated shoulder dislocations. *Acta Chir Orthop Traumatol Cech.* 2010;77(4):327-331.
21. De Giorgi S, Garofalo R, Tafuri S, Cesari E, Rose GD, Castagna A. Can arthroscopic revision surgery for shoulder instability be a fair option? *Muscles Ligaments Tendons J.* 2014;14;4(2):226-231.
22. Yamamoto N, Muraki T, An KN, et al. The stabilizing mechanism of the Latarjet procedure: a cadaveric study. *J Bone Joint Surg Am.* 2013;7;95(15):1390-1397.
23. Rokous JR, Feagin JA, Abbott HG. Modified axillary roentgenogram. A useful adjunct in the diagnosis of recurrent instability of the shoulder. *Clin Orthop Relat Res.* 1972;82:84-86.
24. Bernageau J, Patte D, Debeyre J, Ferrane J. Intérêt du profil glénoïdien dans les luxations récidivantes de l'épaule. *Rev Chir Orthop.* 1976;62(suppl II):142-147.
25. Chuang TY, Adams CR, Burkhart SS. Use of preoperative three-dimensional computed tomography to quantify glenoid bone loss in shoulder instability. *Arthroscopy.* 2008;24(4):376-382