

# Real time evaluation of monolateral clubfoot with sonoelastography. Preliminary results

Salvatore Masala  
Guglielmo Manenti  
Marco Antonicoli  
Daniele Morosetti  
Giulia Claroni  
Giovanni Simonetti

University of Tor Vergata, Department of Diagnostic Imaging, Molecular Imaging, Interventional Radiology and Radiation Therapy, Rome, Italy

## Corresponding author:

Marco Antonicoli  
University of Tor Vergata, Department of Diagnostic Imaging, Molecular Imaging, Interventional Radiology and Radiation Therapy  
Viale Oxford, 81  
00133 Rome, Italy  
e-mail: marcoantonicoli@libero.it

## Summary

**Purpose:** to assess the real time elastosonography (RTE) as a primary diagnostic tool for the evaluation of mechanical properties of Achilles tendons in patients affected by not surgically treated monolateral clubfoot.

**Materials and method:** six patients were evaluated, four males and two females, mean age  $1.2 \pm 1.3$  months, treated with Ponseti method, and afterward, they underwent RTE examination of the Achilles tendon in clubfoot. A following ROI (region of interest) was positioned on the distal third of the tendon and the obtained data was examined retrospectively.

**Results:** in the examined cohort of patients, the mean value ROI 1/mean value ROI 2 ratio was  $2.0 \pm 0.18$ , with an increased red area in the RTE evaluation of the affected tendon, while in the contralateral foot the mean observed value was  $2.50 \pm 2.1$ .

**Conclusion:** RTE is a feasible and simple technique, which allows the study of the mechanical properties of Achilles tendons in children with clubfoot.

*Key words:* clubfoot, elastography, Achilles tendon.

## Introduction

Congenital clubfoot has an incidence of 1:1000 in childhood and it is a common defect of the musculoskeletal system. It consists on the isolated deformity of four components of the foot, equinus foot, hindfoot varus, forefoot adductus, and

cavus (1, 2).

Many theories have tried to explain the etiopathogenesis of idiopathic clubfoot, including vascular deficiencies, genetic factors or multifactorial disease with subsequent muscle abnormalities and tendon insertions (3-7).

The Ponseti method, characterized by Achilles tendon tenotomy and foot abduction bracing, is more likely the preferred treatment for idiopathic clubfoot (8,9).

To our knowledge, there are no current studies investigating the mechanical stiffness properties of Achilles tendons in patients with monolateral clubfoot disease treated with Ponseti method.

Real Time Elastography (RTE), is a technique that can assess the differences of stiffness between diverse tissue and it has recently been suggested to be a useful tool to estimate tissue distortion, muscle and tendons stiffness (10).

Our purpose was to assess the real time elastosonography (RTE), as primary diagnostic tool, in order to evaluate the mechanical properties of Achilles tendons with RTE in patients affected by not surgically treated monolateral clubfoot.

## Materials and methods

### Study population

Six patients affected by monolateral clubfoot treated with Ponseti method without median tenotomy, (4 males and 2 females; mean age  $9.66 \pm 2.42$  months) were consecutively evaluated. The experimental protocol was approved by the Ethics Committee of our institution and written informed consent was obtained from all volunteers in accordance to the Declaration of Helsinki. The first diagnostic step involved the clinical evaluation in orthopedic department and were excluded in presence of a systemic pathological condition. Any patient affected by connective tissue disease, metabolic disease, tendon injury, surgery, or endocrine disease was not considered in the present study. Once selected, patients were referred to Diagnostic Imaging Department for ultrasound and sonoelastography (RTE) examination of bilateral Achilles tendons. The B-mode scan, performed over the entire Achilles tendon from the distal to the proximal myotendinous junction, allowed us to examine the morphological parameters in order to assess any recent or previous traumatic lesions. A subsequent sonoelastography evaluation on the distal third of the tendon was executed.

### Examination protocol

The ultrasound scan and RTE were performed using the same ultrasound system (IU22, Philips Medical Electronics Systems N.V. Corporation) and the same ultrasound probe (7.5 MHz). A radiologist with experience about muscle-

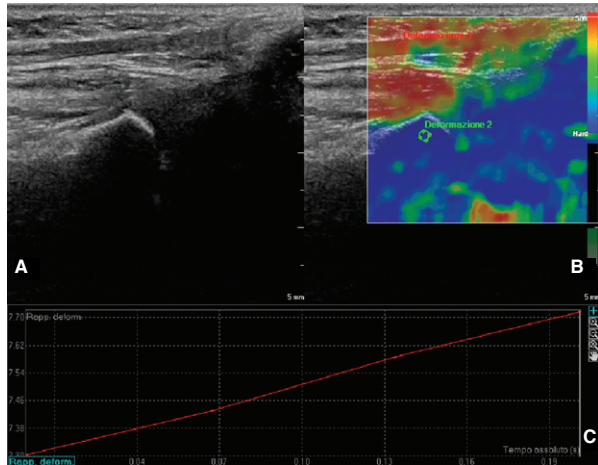


Figure 1. (A) Longitudinal B-mode ultrasound scan and superimposed (B) sonoelastogram of a physiologic distal third of the Achilles tendon. The elastography was evaluated positioning two circular ROIs, of about 3 mm in diameter, respectively on the Achilles tendon and on the bone tissue. (C) The Strain index and the ratio was then calculated between the Achilles tendon and the bone tissue.

skeletal diseases positioned a Region of Interest (ROI) on the Achilles tendon, in axial and longitudinal plane. An indicator in the screen provided the user with real-time feedback on the appropriate amount of deformation for the elastogram. The total amount of deformation used to compute the strain elastogram is the sum of inherent, or physiologic, patient motion plus the external compression of the transducer. It displayed instantaneous or momentary tissue deformation, not final deformation.

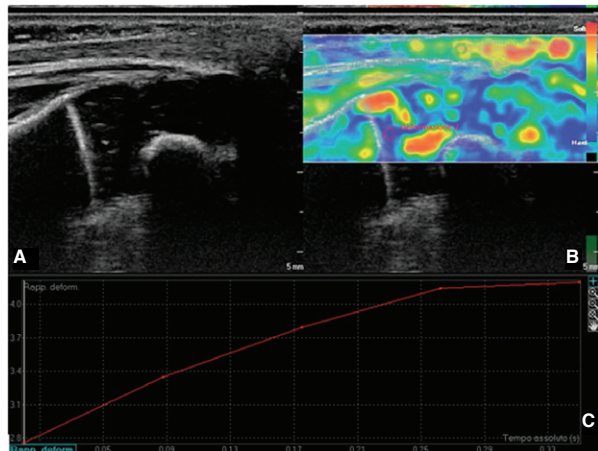


Figure 2. (A) Longitudinal B-mode ultrasound scan and superimposed (B) sonoelastogram of the third distal of the Achilles tendon in a clubfoot showed a diffuse hyperechoic pattern highlighted in gray scale associated with a low elasticity of the structure, evaluated by sonoelastography mode. The elastography was evaluated positioning two circular ROIs, of about 3 mm in diameter each, respectively on the Achilles tendon and on the bone tissue. (C) The Strain index and the ratio was then calculated between the Achilles tendon and the bone tissue.

The elastosonogram analysis began when the strain indicator of the probe expressed the correct pressure of the operator. The colors in the ROI varied from blue to red to show the relative hardness and softness of areas inside the ROI. The probe was kept in position manually while patient was in rest position. The same measurements were performed respectively in the clubfoot and in the contralateral healthy tendon, and was performed by both radiologists in two different consecutive period. The entire examination lasted approximately  $14 \pm 2.8$  minutes for each patient. The color-coded images were analyzed on a personal computer using the QLAB (developed by Philips Medical Systems), which permitted us to selected a 30 frame images/cine-loop and to position two same circle ROI, called 1 and 2, measuring 4 mm in diameter. The reference ROI 2 was positioned in the bone tissue while the ROI 1 in the distal segment of the tendon, measuring the strain index ( $SI=ROI1/ROI 2$ ) (Fig.1; Fig.2; Fig.3; Fig.4). For quantification, all pixel data in the colored image were transformed into a histogram and RTE-

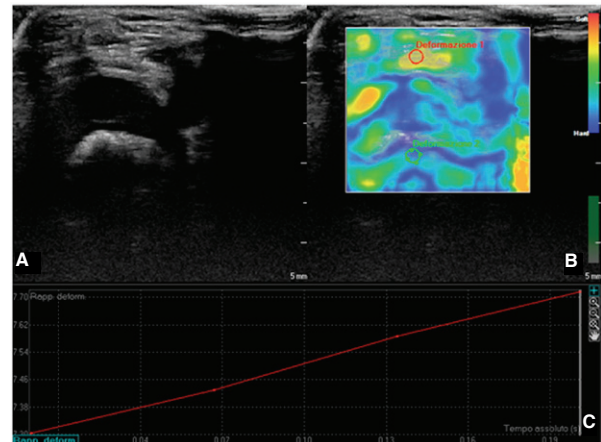


Figure 3. (A) Conventional Axial B-mode ultrasound scan and superimposed (B) sonoelastogram of a physiologic distal third of the Achilles tendon. The elastography was evaluated positioning two circular ROIs, measuring about 3 mm in diameter, respectively on the Achilles tendon and on the bone tissue. (C) The Strain index and the ratio was then calculated between the Achilles tendon and the bone tissue.

Mean elasticity ( $RTE-M^e$ ) values were calculated.  $RTE-M^e$  was described in arbitrary units [a.u.] (Fig.1 C; Fig.2 C; Fig.3 C; Fig.4 C). Analyses were repeated in quadruplicate (one for each acquisition) and results were expressed as the average value of the different results.

### Data analysis

The variation of the continuous parameters was calculated using the T-student test and standard deviation (SD) achieving an average. Categorical data was evaluated using percentage values. The elastographic images with the concomitant histogram were inserted in a table and were reviewed using the statistical software SPSS.

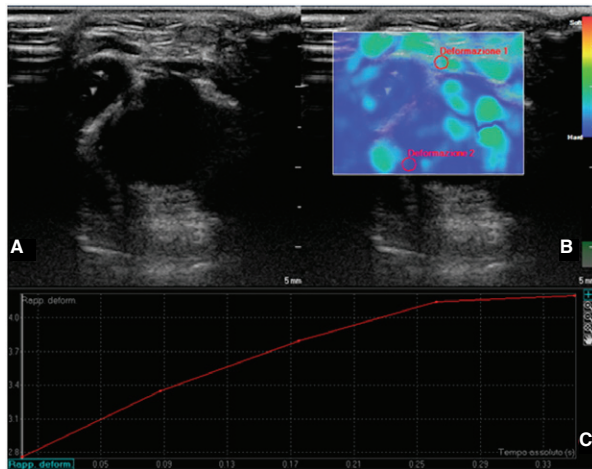


Figure 4. (A) Conventional Axial B-mode ultrasound scan and superimposed (B) sonoelastogram of the distal third of the Achilles tendon in a clubfoot showed a diffuse hyperechoic pattern highlighted in gray scale associated to a low elasticity of the structure, evaluated by sonoelastography mode. The elastography was evaluated positioning two circular ROIs, the diameter was about 3 mm each, respectively on the Achilles tendon and on the bone tissue. (C) The Strain index and the ratio was then calculated between the Achilles tendon and the bone tissue.

#### Patients. Correlation between RTE-M<sup>e</sup> of Achilles tendon in clubfoot and healthy Achilles tendon.

The Achilles tendons were identified in all patients from both legs, therefore it was possible to classify the values and to compare them. The color images was examined, however they were not divided in class and they were used as a guide to obtain the ratio value between ROI 1 and ROI 2. There was not a statistically significant difference between the tendon characteristics and sex. A decrease in the elasticity of the Achilles tendon was observed in clubfoot (Fig.1C; Fig.2 C; Fig.3 C; Fig.4 C). There was a statistically significant difference between results obtained in pathologic Achilles tendon compared to healthy findings. In all children, the mean

Sex and Age	Achilles tendon with clubfoot mean value ROI 1/ man value ROI 2	healthy Achilles tendon mean value ROI 1/ man value ROI 2
M, 13 months	1.8	2.4
F, 8 months	2.3	2.5
M, 6 months	2.1	2.5
M, 11 months	2	2.6
F, 10 months	1.9	2.3
M, 10 months	1.8	2.2
9.66 ± 2.42 (mean value)	1.98 ± 0.2 (mean value)	2.41 ± 0.3 (mean value)

Table 1. Characteristics of the all cohort of patients associated to the mean ROI 1/Mean value ROI 2.

value ROI 1/mean value ROI 2 ratio resulted to be  $1.98 \pm 0.2$  in clubfoot and presented a statistical difference with the ratio in healthy tendon which resulted  $2.41 \pm 0.3$  ( $p < 0.05$ ). See table with patients characteristics (Tab. 1).

#### Discussion

The clubfoot is one of the most common musculoskeletal birth-associated pathologies, however, its etiopathogenesis remains uncertain (11,12). Genetic factors are more likely to be responsible for the development of this pathology (12). In children, the pathologic condition creates several congenital deformities affecting the bone, ligaments and tendons tissue (13). The treatment consists in a medical and surgical approach, named Ponseti, which is performed in infants with defective or absent muscles (12,13). The Ponseti method is widely performed and it consists in stretching the peronei and foot dorsiflexor muscles, in order to improve the normal position of the foot or to maintain a correct posture (13). In our study, through the sonoelastography evaluation, a tensile test has been performed, highlighting, as results, a chronic tendinopathy condition over the Achilles tendon structures. The tendinopathy can soften and weaken the collagen and elastin structure leading to possible rupture (14). Although no signs of achillodynia were observed, a decrease of Achilles tendons elasticity in clubfoot was noted. This data was probably due to a genomic alteration of the structure. The B-mode ultrasound allowed us to study features of Achilles tendons while the sonoelastography showed low elasticity values along the tendon structure compared to the healthy contralateral tendon (15). US alone presents a high sensitivity and specificity in the detection of intratendinous alterations, therefore the sonoelastography can help for a better detection of Achilles tendinopathy and characterization of physiologic and pathologic findings (16). The main alterations were observed on the distal portion of the tendons, which is represented by a weaker structure, at rest position, without evaluation of the stiffer proximal portion (17). In the evaluated tendons, a strongly inhomogeneous pattern was highlighted, probably related to the different mechanical properties of the various tissue components within the normal and pathologic tendons (18). Previous magnetic resonance studies reported inhomogeneous appearance, especially in the distal portion, with different viscoelastic properties (18). These findings have been confirmed by US evaluation and sonoelastography, moreover adding at rest behaviour. In the present study, a strong correlation was found between the age and the RTE appearances, while no influence of sex was noted. The main limit of the study was the lack with histopathologic findings of Achilles tendons alteration in clubfoot, the retrospective nature of the study, the small number of patients and the lack of the double-blind nature of the study.

#### Conclusion

RTE is a feasible and simple technique which allows to study the mechanical properties of Achilles tendons in children with clubfoot, including the evaluation of inhomogeneous or relatively homogeneous patterns. The strain index can be

use as a comparative index between healthy tendons and clubfoot tendons, and it represents a valid technique in the clinical practice. This study reports preliminary results and future long-term follow-up studies are required.

## References

1. Wynne-Davies R. Family studies and the cause of congenital club foot, talipes equinovarus, talipes calcaneo-valgus and metatarsus varus. *J Bone Joint Surg Br.* 1964; 46: 445-463.
2. Chu A, Lehman WB. Persistent clubfoot deformity following treatment by the Ponseti method. *J Pediatr Orthop B.* 2012; 21(1):40-46.
3. Hootnick DR, Levinsohn EM, Crider RJ, Packard DS Jr. Congenital arterial malformation associated with clubfoot. A report of two cases. *Clin Orthop Relat Res.* 1982; 167:160-163.
4. Bechtol CO, and Mossman HW. Clubfoot; an embryological study of associated muscle abnormalities. *J Bone Joint Surg.* 1950; 32(A:4): 827-838.
5. Dobbs MB, Gurnett CA. Genetics of clubfoot. *J Pediatr Orthop B.* 2012;21(1):7-9.
6. Stewart SF. Clubfoot: Its incidence, cause and treatment. An anatomical-physiological study. *J Bone Joint Surg.* 1951; 33-4(3): 577-590.
7. Hirsch C. Observation on early operative treatment of congenital club-foot. *Bull Hosp Joint Dis.* 1960; 21:173-180.
8. Flynn JM, Donohoe M, Mackenzie WG. An independent assessment of two clubfoot classification system. *J Pediatr Orthop.* 1998; 18(3): 323-327.
9. Ponseti IV. Treatment of congenital club foot. *J Bone Joint Surg Am.* 1992; 74(3); 448-454.
10. Frey H. Realtime elastography. A new ultrasound procedure for the reconstruction of tissue elasticity. *Radiologe* 2003; 43(10): 850-855.
11. Laaveg SJ, Ponseti IV. Long-term results of treatment of congenital club foot. *J Bone Joint Surg Am.* 1980; 62(1): 23-31.
12. Dobbs MB, Gurnett CA. Update on clubfoot: etiology and treatment. *Clin Orthop Relat Res.* 2009; 467(5):1146-1153.
13. Ponseti IV, Campos J. The classic: observations on pathogenesis and treatment of congenital clubfoot. 1972. *Clin Orthop Relat Res.* 2009; 467(5): 1124-1132.
14. Klauser AS, Faschingbauer R, Jaschke WR. Is sonoelastography of value in assessing tendons? *Semin Musculoskelet Radiol.* 2010; 14(3): 323-333.
15. Palle L, Reddy MB, Reddy KJ, Kumari MV. Technical note: Real-time sonoelastography evaluation of Achilles tendon. *Indian J Radiol Imaging.* 2011; 21(4): 267-269.
16. De Zordo T, Chhem R, Smekal V et al. Real-Time sonoelastography: findings in patients with symptomatic Achilles tendons and comparison to healthy volunteers. *Ultraschall Med.* 2010; 31(4): 394-400.
17. Tan S, Kudaş S, Ozcan AS, et al. Real-time sonoelastography of the Achilles tendon: pattern description in healthy subjects and patients with surgically repaired complete ruptures. *Skeletal Radiol.* 2011 Dec 14 [Epub ahead of print].
18. Drakonaki EE, Allen GM, Wilson DJ. Real-time ultrasound elastography of the normal Achilles tendon: reproducibility and pattern description. *Clin Radiol.* 2009; 64(12): 1196-1202.

### *Conflict of interest*

*The Authors have no commercial, proprietary or financial interest in any products or companies described in this article.*